

The V position versus sitting position in craniotomy cases

The V position in craniotomy

Ayşe Mızrak Arslan, Elzem Sen, Merve Esra Kara, Berna Kaya Uğur

Department of Anesthesiology and Reanimation, University of Gaziantep, School of Medicine, Gaziantep, Turkey

Abstract

Aim: In this study, the researchers aimed to investigate satisfaction of anesthetists with the alternative V position compared to the sitting position in neuro-anesthesia, as well as the number of VAE and complications and hemodynamics changes, and compare these results to clinical impact and side effect rates obtained in other studies in the literature still using the sitting position. **Material and Methods:** The data of a total of 78 patients aged between 20-70 years, classified as ASA I, II or III who underwent a craniotomy operation for tumor (74 patients) or neurovascular lesion (4 patients) in the V position in the researchers' clinic between January 2011 and December 2015 were examined retrospectively and assessed in a case series plan. **Results:** During the study, records of 78 patients who have had a craniotomy operation in the alternative V position were analyzed (n=78). Forty-one (52.5%) and 37 (47.5%) of the patients were male and female, respectively. Venous air embolisms or pulmonary embolisms were not observed in any patient. The satisfaction of the practicing anesthetist was 100% median min-max: 1.0 (1.0-1.0). **Discussion:** In this study, the V position, which was used as an alternative to the sitting position, provided the advantages of the sitting position through elaborate anesthesia applications and surgical planning and additionally removed the risk of complications such as VAE, post-operative quadriplegia, tension pneumocephalus, subdural hematoma, and peripheral nerve injuries. **Conclusion:** The use of V position proposed by this research as an alternative in neurosurgery cases requiring the sitting and prone positions, provided the necessary advantages to neurosurgeons, improved the patient's venous drainage, offered better vision of the surgical site and enables less bleeding in the patient, did not develop any VAE, decreased the need for cerebellar retraction in posterior fossa cases and minimized or inhibited pre-operative mortality through low intracranial pressure.

Keywords

Neurosurgery; Alternative V Position; Neuroanesthesia; VAE

DOI: 10.4328/ACAM.20069 Received: 2019-10-30 Accepted: 2020-01-08 Published Online: 2020-01-20 Printed: 2020-09-01 Ann Clin Anal Med 2020;11(5):385-389
Corresponding Author: Berna Kaya Uğur, Department of Anesthesiology and Reanimation, University of Gaziantep, School of Medicine, Sahinbey, Gaziantep, Turkey
E-mail: metegurolugur@hotmail.com GSM: +905325727651
Corresponding Author ORCID ID: <https://orcid.org/0000-0003-0044-363X>

Introduction

The use of the sitting position in neuroanesthesia in craniotomy operations is still a matter of debate. The head-up sitting position of patients offers certain advantages to neurosurgeons; however, it constitutes various difficulties for anesthetists. It shortens the duration of surgery and decreases the loss of blood as it facilitates access to the lesion, enables cerebral venous drainage and reduces intracranial pressure. However, it is known that the sitting position leads to severe complications such as hypotension, venous air embolism (VAE), pneumocephalus and peripheral neuropathy [1]. The incidence of VAE has been reported to range from 7% to 76% in the sitting position [2] and as 21% in the semi-sitting position [3]. There is no evidence that one position is superior to another, and suitable surgical results can be obtained with each position. The V position, which is an alternative to the sitting position, is a position developed with the aim of providing convenience to surgeons in the researchers' clinic and of preventing complications that might be fatal (VAE, hypotension, pneumocephalus, peripheral neuropathy). In this study, the researchers aimed to investigate the satisfaction of anesthetists with the alternative V position compared to the sitting position in neuroanesthesia, as well as the number of VAE and complications and hemodynamics changes, and compare these results to clinical impact and side effect rates obtained in other studies in the literature still using the sitting position.

Material and Methods

The data of a total of 78 patients aged between 20-70 years, classified as ASA (American Society of Anesthesiologists) I, II or III and had a craniotomy operation for tumor (74 patients) or neurovascular lesion (4 patients) in the V position in the researchers' clinic between January 2011 and December 2015 were examined retrospectively, and assessed in a case series plan. Patients who had heart failure, liver-kidney failure, anemia and thrombocytopenia, and who did not want to be enrolled were excluded from the study.

The alternative V position is defined as a position in which an angle of 45 degrees is created between the vertical line of the ground where the patient sits and the thorax is leaned, and an angle of 45 degrees is created between the surface where upper legs are leaned upon and the vertical line of the ground. In other words, the angle between thorax and upper legs is a total of 90 degrees; however, the angle between the thorax and the operating table and between the upper legs and the operating table is 45° and 45°, respectively. In this position, the angle between knees and shoulders/neck is still 80°- 90°.

As for the demographic details of the patients, gender (n, %), age (years) and body mass indices (BMI, kg/m²) were determined and recorded. Gender was coded 0 for women and 1 for men. After the general anesthesia, information and the position technique were explained and written informed consent was obtained from the patients, the patients were monitored via ECG, non-invasive blood pressure measurement and pulse oximetry. A 20G peripheral venous catheter (I.V. FLON®, La-med Healthcare Pvt. Ltd., Haryana, India) was placed on the dorsal surface of the left hand. Saline solution (0.9%; 200 ml) was

given to the patients every hour. Patients inhaled 100% O₂ for general anesthesia and 3-4mg/kg sodium thiopental (Pental Sodium®, 0.5 g Vial, İbrahim Etem Ulugay İlaç Sanayi Türk A.Ş., Turkey), 2 mcg/kg fentanyl citrate (Talinat®, 0.5 mg/10 ml, Vem İlaç, Turkey) and 0.5 mg/kg rocuronium bromide (Curon®, 50 mg/ml, Mustafa Nevzat İlaç Sanayi A.Ş., Turkey) were administered intravenously (iv) as muscle relaxants. Ventilation with a mask was applied for three minutes, and female and male patients were intubated with 7.5 mm endotracheal tube and 8.5 mm spiral endotracheal tube (GALENA®, Hamburg, Germany), respectively. The endotracheal cuff was inflated with the lowest pressure to inhibit air leak during ventilation. A tube test was performed after confirming via the bilateral auscultation of thorax that the tube was in the trachea, and both lungs were ventilated evenly. Maintenance of the patients' anesthesia was ensured with 2% sevoflurane (Sevorane liquid® 100%, 250 ml, solution, Abbvie Tıbbi İlaçlar San. Tic. Ltd. Şti, Italy), 50% O₂ 50% air and 0.05 mcg/kg/min remifentanyl (Rentanil®, 5 mg vial, Vem İlaç, Turkey). Afterwards, the left radial artery catheterization was performed using a 22G cannula (I.V. FLON®, La-med Healthcare Pvt. Ltd., Haryana, India). Invasive arterial blood pressure was monitored via the left radial artery using a disposable pressure transducer kit (OKUMAN®, SCW Medica Ltd, Guangdong, China). Zero point of invasive arterial blood pressure kit was determined at the level of the mastoid process. A 7F Arrow 3-lumen catheter (Arrow International Inc, Reading, PA) was used for central venous catheterization. Zero point of central venous pressure (CVP) transducer was kept at heart level (the point at which left 4-5 intercostal space intersects with anterior axillary line). CVP values were first measured and recorded in patient placed in the supine position. Later, the values were measured and recorded again in the patient placed in V position. The difference of CVP due to the change of position was recorded. All invasive catheterization procedures were performed by the same experienced anesthetist while another anesthetist recorded the assessments and measurements. Fentanyl (0.5 mcg/kg) was administered intravenously to the patients before the fixation of head, and a distance of 4-5 cm was kept to prevent excessive flexion between the chin and sternum and potential venous return of the brain. Elastic bandages were used around the legs of the patients to prevent venous lake. All potential points of pressure were supported using pads. At the end of the surgery, the patients were returned to supine position and extubated by reversing the neuromuscular block with 0.06 mg/kg of neostigmine (Plantigmin®, 0.5 mg/ml of Polifarma, Turkey) and 0.02 mg/kg of atropine (Atropine Sulfate®, 1/2 mg 1 ml, Galen, Turkey). All patients were extubated and transferred to the intensive care unit.

Pre-operative, intraoperative, and post-operative body temperatures, total crystalloid and colloid amount administered to the patient, blood gas values measured at intervals of thirty minutes and any complications were recorded.

The central venous pressure (CVP), mean arterial blood pressure (MAP) and heart rate (HR) were recorded before and after the V position. The parameters required for the monitorization of air embolism (ETCO₂, PaO₂, HR, MAP) were monitored intraoperatively. The VAE was defined as a decrease in end-tidal PCO₂ value at or above 0.7 kPa (5.25 mmHg).

Also, the satisfaction of the anesthetists, as well as the number (n) and frequency (%) of venous air embolism and other complications were investigated. Satisfaction of the anesthetists was coded as 1 for “satisfied”, and 0 for “not satisfied”.

Statistics

Statistical analysis was done using STATA 11.2 (Statacorp, Texas, USA). The data were represented as mean value [with standard deviation (SD)], median value [with range] or as a number [with percentage]. The Chi-square analysis was performed to compare categorical variables. Non-parametric numerical data were analyzed using the Mann-Whitney U test. P- value <0.05 was considered statistically significant.

Results

During the study, records of 78 patients who had a craniotomy operation in the alternative V position were analyzed (n=78). Forty-one (52.5%) and 37 (47.5%) of the patients were male and female, respectively. The mean age was 47.3±14 years. The mean Body Mass Index (BMI) of the patients was 22.8±3.6 kg/m2 (Table 1).

Venous air embolisms or pulmonary embolisms were not observed in any patient. The satisfaction of the practicing anesthetist was 100% median min-max: 1.0 (1.0-1.0) (Table 2). The CVP, MAP, and HR values were compared in mean±SD value before and after the V position. It was found that the CVP value was 6 cmH2O before positioning and 3 cmH2O after positioning. While the mean of MAP values was 93 mmHg before positioning, it decreased to 83 mmHg after positioning. HR was recorded as 83 beats per minute before positioning and as 80 beats per minute after positioning (Table 3, Figure 1).

Discussion

There is still debate as to the optimum position of patients for lesions in the posterior fossa, occipital or occipitoparietal localizations during neurosurgical interventions. Although the use of the sitting position for neurosurgery is gradually decreasing, some centers still commonly use this position. It was seen that cranial nerve function was preserved better and less blood loss occurred with the sitting position in neurosurgery [4]. Enabling an optimal surgical application, the sitting position restored cerebral venous drainage while decreasing the risk of cranial nerve damage and tissue retraction [5]. However, complications such as bradycardia, pneumocephalus, subdural hematoma and quadriplegia, and primarily venous air embolism were reported in surgeries with the sitting position [4,5]. VAE might occur when large open veins are exposed to the atmosphere and surgical site in such veins is above the horizontal level of heart. When the surgical site is above the heart level, intravenous pressure might be sub-atmospheric and air intake through these open veins might occur during surgery. Generally, this risk is best described in neurosurgery procedures in the sitting position where there is a height difference between the surgical site and heart, and venous sinuses cannot be compressed [6]. In a published review, Fathi et al. reported the incidence of VAE as 39% during posterior fossa surgeries in the sitting position [7]. The main issue in the sitting position is VAE, and various methods, such as clinical observation, monitorization

Table 1. Demographic Data of the Patients Operated in New V Position

Gender (M/F) (%)	41/37 (52.5%/47.5%)
Age (Year)	47.3 ± 14.0
BMI (Body Mass Index)	22.8±3.6

n=78

Table 2. The Satisfaction Score of the Anesthetist, the Number and the Frequency of Venous Air Embolism during V Position.

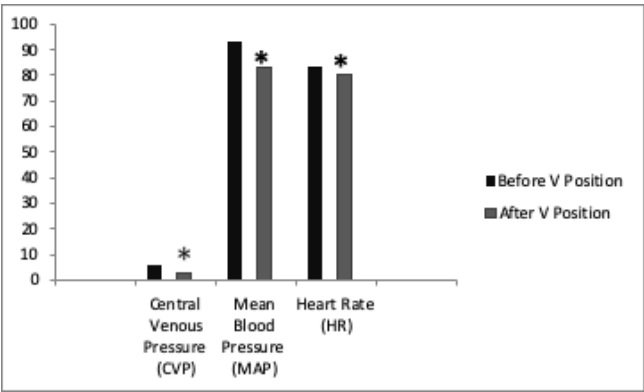
V position	
The Number and the Frequency of Venous Air Embolism (n) (%)	0 (0.0%)
The Satisfaction of Anesthetists Median (min-max)	1.0 (1.0-1.0)
The Number and the Frequency of Other Complications (n) (%) (pneumocephaly, hypotension, quadriplegia, peripheric nerve injury)	0 (0%)

n=78

Table 3. The Comparison of Central Venous Pressure (CVP), Mean Blood Pressure (MAP) and Heart Rate (HR) with the Values Before V Position and After V Position

V position				
CVP (cmH2O)	6.4±3.3	3.9±2.5	5.0±2.1	0.0001
MAP (mmHg)	93	83	82	0.0001
HR (Beat/min)	83	80	73	0.02

n= 78
*p< 0.05 when compare the CVP values before V position and after V position
*p< 0.05 when compare the CVP values before V position and after V position+ colloid fluid infusion



There was a statistical significant difference between the value of CVP, MAP,HR before V position (supine position) and CVP, MAP,HR after V position.
*p<0.05

Figure 1. The Comparison of Central Venous Pressure (CVP), Mean Blood Pressure (MAP) and Heart Rate (HR) with the Values Before V Position and After V Position

(arterial tension, pulse, end-expiratory carbon dioxide), TEE (transesophageal echocardiography) and precordial Doppler are used to detect it [8]. Accordingly, there are different results regarding the incidence of VAE. In their study conducted on pigs, Schafer et al. found the rate of VAE as 52.8% with TEE and 46.8% with precordial Doppler [9]. In a study by Dilmen et al., they reported the incidence of VAE in adults who had neurosurgery in the sitting position as 20.4% [10]. Some other studies advocated that EtCO₂ monitoring was sufficient alone for monitorization in the sitting position [11]. A decrease of 3 to 5 mmHg in EtCO₂ was used for the diagnosis of VAE [4,12]. In this current study, the EtCO₂ decrease and clinical evaluations (hypotension, bradycardia) were used for the diagnosis of VAE. Pre-existing hypovolemia is, though slightly, associated with VAE [11]. With regards to intraoperative fluid management, colloids were thought to be superior to crystalloids in increasing intravascular volume in patients who had pre-existing hypovolemia [13]. Fluid filling with hydroxyethyl starch (HES) boluses resulted in positive responses in cardiac and stroke volume index during the sitting position. It was thought that a smaller volume of HES than crystalloids and a less positive fluid balance were important in craniotomy patients with decreased brain compliance [14]. In this current study, the researchers met the patient's need for intravenous maintenance fluid with NS for 50% and HES for 50%. Hemodynamic changes in patients who underwent neurosurgical operation under general anesthesia might occur both in the sitting position and prone position [15]. Harrison et al. reported the incidence of intraoperative hemodynamic instability as 24.1% in posterior fossa surgeries in the sitting position [11]. Gupta et al. found the rate of hemodynamic instability as 12.3% and reported that the rates were diverse, as definitive criteria of hemodynamic instability were different [15]. Dilmen et al. reported that 37.6% of adult patients undergoing neurosurgical operation developed hypotension when the supine position was switched to the sitting position [10]. These hemodynamic changes are essentially associated with a reduced preload. Upright position causes a shift from the intrathoracic space to the extrathoracic space. This decreases cardiac output and mean arterial pressure [16].

In this current study, the researchers observed that physiological hemodynamic responses altered at the moment the V position was applied in patients who were under general anesthesia. CVP values were found as 6.4 ± 3.3 on average in the supine position, 3.9 ± 2.5 after V positioning and 5.0 ± 2.1 after colloid fluid infusion in the V position.

We believe that this decrease, which is much less than the decrease amounts in the literature, may have mitigated or even prevented the possibility of venous air embolism.

In this current study, a 45-degree elevation of lower limbs in the position, which resembles the letter V, enables the abdomen to be under a slight pressure between the thorax and upper limbs. This compression is also reflected in the V. Cava Inferior in the abdominal region and increases CVP in the patient [17]. CVP, increasing with this mechanism, makes the incidence of air embolism lower than expected. Compared to the sitting position, the V position also prevents CVP to decrease more by shortening the distance between heart and operating table as

well as decreasing the possibility of air embolism [18].

The sitting position enables optimum access to posterior fossa lesions, improves venous and cerebrospinal fluid drainage, reduces intracranial pressure, decreases airway pressure, improves access to endotracheal tube and enables observation of face for cranial nerve stimulations during the neurosurgery [1]. In this current study, the V position, which was used as an alternative to the sitting position, provided the advantages of the sitting position to neurosurgeons through elaborate anesthesia applications and surgical planning, and additionally removed the risk of complications which could lead to destructive results such as VAE, post-operative quadriplegia, tension pneumocephalus, subdural hematoma and peripheral nerve injuries [19,20].

Stabilization of hemodynamics in the prone position is one of the most troublesome positions as the preservation of intravenous lines and the tracheal tube is difficult. Access to patients' airway is not easy. Pressure sores, vascular compression, brachial plexus injuries, air embolism, blindness and quadriplegia are among other reported complications [5]. Jadik et al. defined the semi-sitting position as the flexion of hip up to maximum 90 degrees, positioning legs and feet above the head, reclining upper body as much as possible and forward flexion of the head [1]. Feigl et al. reported that, although air bubbles were detected in 55.7% of patients on TEE in this position, they could not aspirate air with central venous catheter and did not experience a clinically significant VAE. However, they emphasized that the potential risk of VAE remained in the semi-sitting position and complications should be observed [21].

VAE might occur in all positions when there is an open vein and a venous pressure gradient occurs between heart and operation site. In this current study, the patients' legs up with a 45-degree angle in the V position increased central venous pressure by increasing the return of volume which has the potential to form a lake in legs (like a colloid effect) to the heart [39]. It is thought that the development of VAE can be inhibited through the increase of central venous pressure [23].

Consequently, the use of V position proposed by this research as an alternative in neurosurgery cases requiring the sitting and prone positions, provided the necessary advantages to neurosurgeons, improved the patient's venous drainage, offered better vision of the surgical site and enables less bleeding in the patient, did not develop any VAE, decreased the need for cerebellar retraction in posterior fossa cases and minimized or inhibited pre-operative mortality through low intracranial pressure. Therefore, the researchers believe that the alternative V position would provide great benefits in neurosurgeries that are to be performed with the sitting position.

Scientific Responsibility Statement

The authors declare that they are responsible for the article's scientific content including study design, data collection, analysis and interpretation, writing, some of the main line, or all of the preparation and scientific review of the contents and approval of the final version of the article.

Animal and human rights statement

All procedures performed in this study were in accordance with the ethical standards of the institutional and/or national research committee and with the 1964 Helsinki declaration and its later amendments or comparable ethical standards. No animal or human studies were carried out by the authors for this article.

Funding: None

Conflict of interest

None of the authors received any type of financial support that could be considered potential conflict of interest regarding the manuscript or its submission.

References

- Jadik S, Wissing H, Friedrich K, Beck J, Seifert V, Raabe A. A standardized protocol for the prevention of clinically relevant venous air embolism during neurosurgical interventions in the semisitting position. *Neurosurgery*. 2009; 64(3): 533-8.
- Leslie K, Hui R, Kaye AH. Venous air embolism and the sitting position: a case series. *J Clin Neurosci*. 2006; 13(4): 419-22.
- Saladino A, Lamperti M, Mangraviti A, Legnani FG, Prada FU, Casali C, et al. The semisitting position: analysis of the risks and surgical outcomes in a contemporary series of 425 adult patients undergoing cranial surgery. *J Neurosurg*. 2017; 127(4): 867-76.
- Rath GP, Bithal PK, Chaturvedi, Dash HH. Complications related to positioning in posterior fossa craniectomy. *J Clin Neurosci*. 2007; 14: 520-5. DOI: 10.1016/j.jocn.2006.02.010
- Rozet I, Vavilala MS. Risks and benefits of patient positioning during neurosurgical care. *Anesthesiol Clin*. 2007; 25(3): 631-x.
- Kapruch CJ, Abcejo AS, Pasternak JJ. The relationship between end-expired carbon dioxide tension and severity of venous air embolism during sitting neurosurgical procedures- A contemporary analysis. *J Clin Anesth*. 2018; 51: 49-54.
- Fathi AR, Eshtehardi P, Meier B. Patent foramen ovale and neurosurgery in sitting position: a systematic review. *Br J Anaesth*. 2009; 102(5): 588-96.
- Brull SJ, Prielipp RC. Vascular air embolism: A silent hazard to patient safety. *J Crit Care*. 2017; 42: 255-63.
- Schafer ST, Lindemann J, Brendt P, Kaiser G, Peters J. Intracardiac transvenous echocardiography is superior to both precordial doppler and transesophageal echocardiography techniques for detecting venous air embolism and catheter-guided air aspiration. *Anesth Analg*. 2008;106(1):45-54.
- Dilmen OK, Akcil EF, Tureci E, Tunalı Y, Bahar M, Tanrıverdi T, et al. Neurosurgery in the sitting position: retrospective analysis of 692 adult and pediatric cases. *Turk Neurosurg*. 2011; 21(4): 634-40.
- Harrison EA, Mackersie A, Ewan MC, Facer E. The sitting position in neurosurgery in children: A review of 16 years'experience. *Br J Anaesth*. 2002; 88: 12-7.
- Girard F, Ruel M, McKenty S, Boudreault D, Chouinard P, Todorov A, et al. Incidences of venous air embolism and patent foramen ovale among patients undergoing selective peripheral denervation in the sitting position. *Neurosurgery*. 2003; 53: 316-20.
- Verheij J, van Lingen A, Beishuizen A, Christiaans HM, de Jong JR, Girbes AR, et al. Cardiac response is greater for colloid than saline fluid loading after cardiac or vascular surgery. *Intensive Care Med*. 2006; 32: 1030-8.
- Lindroos AC, Nilya T, Silvasti-Lundell M, Randell T, Hernesniemi J, Niemi TT. Stroke volume-directed administration of hydroxyethyl starch or Ringer's acetate in sitting position during craniotomy. *Acta Anaesthesiol Scand*. 2013; 57(6): 729-36.
- Gupta P, Rath GP, Prabhakar H, Bithal PK. Complications related to sitting position during pediatric neurosurgery: An institutional experience and review of literature. *Neurol India*. 2018; 66(1): 217-22.
- Buhre W, Weyland A, Buhre K, Buhre K, Kazmaier S, Mursch K, et al. Effects of the sitting position on the distribution of blood volume in patients undergoing neurosurgical procedures. *Br J Anaesth*. 2000; 84: 354-7.
- Dabrowski W. Changes in intraabdominal pressure and central venous and brain venous blood pressure in patients during extracorporeal circulation. *Med Sci Monit*. 2007; 13(12): 548-54.
- Wyoski MG, Covey A, Pollak J, Rosenblatt M, Aruny J, Denbow N. Evaluation of various maneuvers for prevention of air embolism during central venous catheter placement. *J Vasc Int Radiol*. 2001; 12(6):764-6.
- Himes BT, Mallory GW, Abcejo AS, Pasternak J, Atkinson JLD, et al. Contemporary analysis of the intraoperative and perioperative complications of neurosurgical procedures performed in the sitting position. *J Neurosurg*. 2017; 127(1): 182-8.
- Gale T, Leslie K. Anesthesia for neurosurgery in the sitting position. *J Clin Neurosci*. 2004; 11(7): 693-6.
- Feigl GC, Decker K, Wurms M, Krischek B, Ritz R, Unerti K, et al. Neurosurgical procedures in the semisitting position: evaluation of the risk of paradoxical venous air embolism in patients with a patent foramen ovale. *World Neurosurg*. 2014; 81(1): 159-64.
- Fredholm M, Jørgensen K, Houlitz E, Ricksten E. Load-dependence of myocardial deformation variables-a clinical strain -echocardiographic study. *Acta Anaesthesiol Scand*. 2017; 61(9): 1155-65.
- McCarthy CJ, Behraves S, Naidu SG, Oklu R. Air Embolism: Practical Tips for Prevention and Treatment. *J Clin Med*. 2016; 5(11): 93.

How to cite this article:

Ayşe Mızrak Arslan, Elzem Sen, Merve Esra Kara, Berna Kaya Uğur. The V position versus sitting position in craniotomy cases. *Ann Clin Anal Med* 2020;11(5):385-389